

PANCREATIC ADENOCARCINOMA



Georgetown University Hospital CyberKnife® Team:

Medical Oncologist: John Marshall, M.D.

Radiation Oncologist: Gregory J. Gagnon, M.D.

Medical Physicists: Michael S. Lundsten, M.Sc.
Sonja Dieterich, Ph.D.

Radiation Therapists: Sosena Asrat, R.T.(T.)
Gerard Elie, R.T.(T.)

CyberKnife Center: Georgetown University Hospital
Washington, DC

PANCREATIC ADENOCARCINOMA

DEMOGRAPHICS

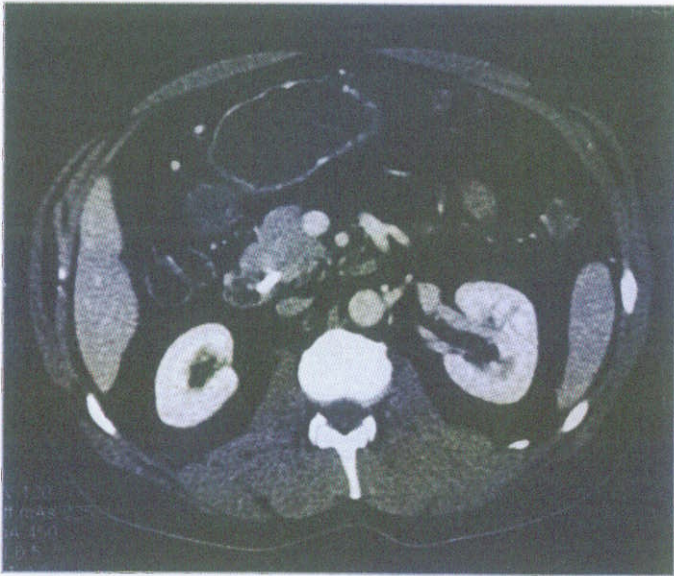
Sex: Male
Age: 54 years
Histology: Unresectable, pancreatic adenocarcinoma

CLINICAL HISTORY

Referred by: Self referral
Previous Treatment: External beam radiation of 54 Gy in multiple fractions, plus chemotherapy

Case History

The patient was in good health until he developed generalized pruritis and jaundice with a bilirubin level in the 5-7 mg/dl range. An elevated gastrointestinal cancer antigen (CA19-9) serum level of 189 units/ml was obtained. A CT scan with 3D reconstruction of the pancreas revealed a 2.5-cm mass AP within the uncinate process abutting the superior mesenteric artery (SMA) medially and the common bile duct (CBD) laterally. A 2 x 1 cm lymph node was identified within the portacaval space. An ultrasound-guided fine needle aspiration (FNA) revealed adenocarcinoma. A cholecystectomy was performed. Another 3D scan 3 days later revealed involvement of the superior mesenteric vein (SMV) with occlusive thrombus and tumor involving approximately 180 degrees of the SMA, although the vessel remained patent.

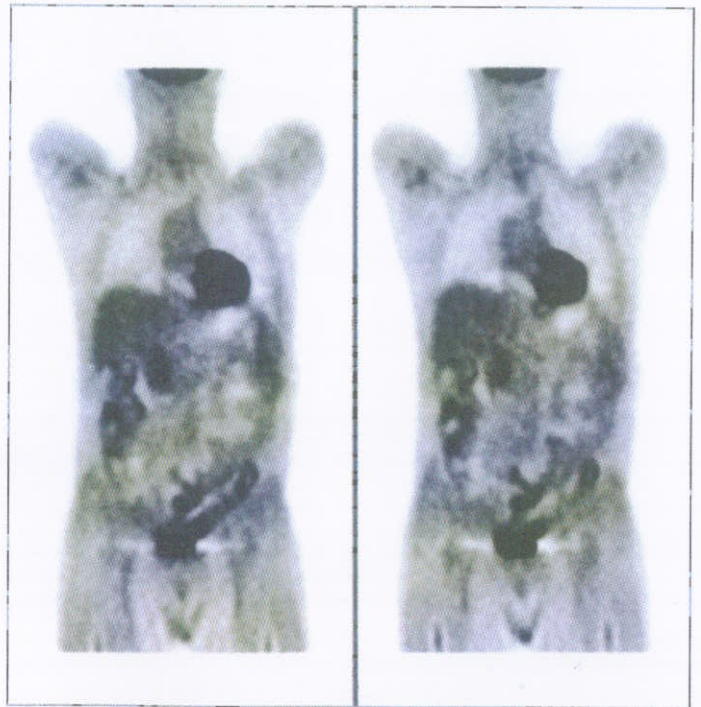


Pretreatment CT showing the pancreatic mass, which measured 2.5 cm AP. A biliary stent is seen in place. The tumor was deemed unresectable because of involvement of the SMA and SMV.

CyberKnife® Treatment Rationale

The patient was not felt to be a resection candidate due to the involvement of the SMA and the SMV. He was treated with chemotherapy – continuous-infusion 5-FU, cisplatin (30 mg/m²) and interferon alpha throughout radiotherapy (see Previous Treatment, above). Radiotherapy was followed by postoperative chemotherapy – gemcitabine, Taxotere and Xeloda – which caused bone marrow suppression issues. Post-standard RT treatment, the pancreatic mass increased in size to 2.8 cm AP (compared to the previous 2.5 cm).

CyberKnife® radiosurgery was felt to be a reasonable treatment which might render the disease inactive or perhaps allow for subsequent surgery.



Pretreatment PET obtained on showing a positive FDG uptake in the pancreas.

TREATMENT DETAILS

Tumor Volume: 33.31 cc
Imaging Technique(s): CT
Rx Dose & Isodose: 24 Gy to 81%
Conformality Index: 1.56
Tumor Coverage: 97.2% of PTV
Number of Beams: 278

Fractions / Treatment Time: 3 / 115 minutes average
Path Template: 3 path 900_1000 mm
Tracking Method: 6D fiducial tracking
Collimator(s): 15 mm

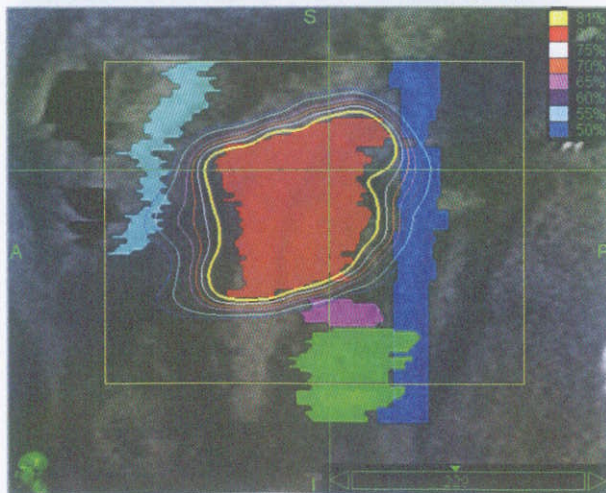
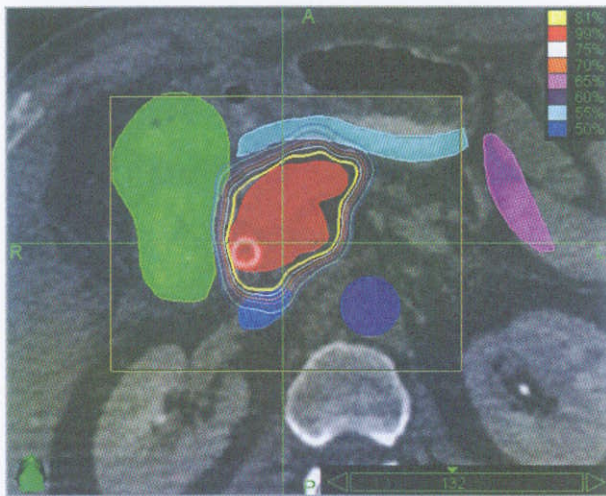
Planning Process and Goals

The 81% isodose line represents the prescribed dose of 24 Gy to the tumor. The treatment plan provided a 1.56 conformality index. Tumor coverage was 97.2% of the planning treatment volume. The tumor and the critical structures (duodenum, stomach, bowel, aorta and inferior vena cava (IVC)) were contoured for dose calculation purposes. An optimized inverse treatment plan was created such that the 81% isodose contour provided a conformal index of 1.56 while minimizing dose to the critical structures.

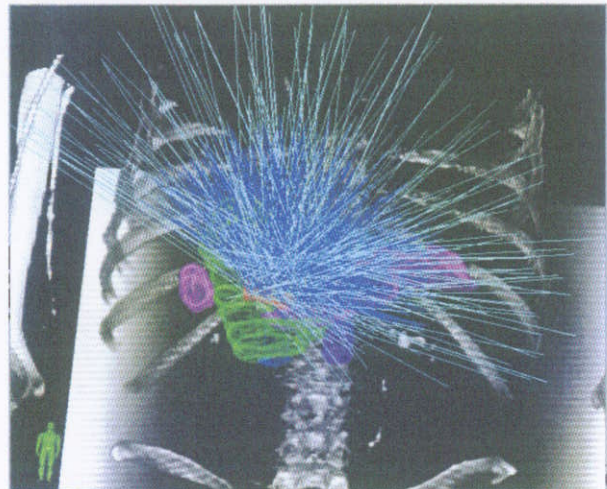Treatment Delivery

The patient was treated with 24 Gy to the 81% isodose line in three daily fractions. This treatment was five months after completion of initial radiation therapy and chemotherapy and seven months after initial symptoms. The planning CT for CyberKnife revealed that the prior standard RT and chemotherapy had not reduced the size of the tumor, though the size appeared to have stabilized.

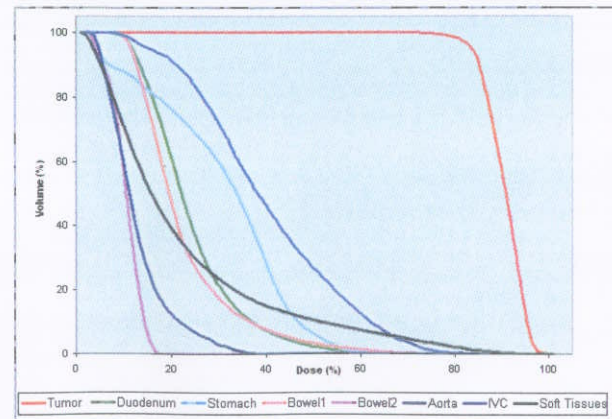
The patient tolerated his treatment with no morbidity other than some fatigue.



Axial and sagittal planning images with the tumor, isodose curves, and critical structures reconstructed from 1 mm sections. Note the highly conformal dose distribution to the pancreas avoids the aorta (violet), IVC (blue), duodenum (green), stomach (light blue) and bowel (pink and coral).



Rendering of the CyberKnife's beam positions for the treatment of the pancreas from an anterior view point.



Dose volume histogram (DVH) for tumor and critical structures.