


LEFT OPTIC NERVE MENINGIOMA (WHO GRADE 2)



Barrow Neurological Institute CyberKnife® Team:

Radiation Oncologists: John Kresl, M.D., Ph.D.

Surgeon: Randal Porter, M.D.

Medical Physicist: Raymond Rodebaugh, Ph.D.

Radiation Therapist: Nancy Berstein, R.T.(T.)

Additional Contributors: Debra Traylor

CyberKnife Center: Saint Joseph Hospital
Barrow Neurological Institute
Phoenix, AZ

LEFT OPTIC NERVE MENINGIOMA (WHO GRADE 2)

DEMOGRAPHICS

Sex: Male
Age: 75 years
Histology: Meningioma

CLINICAL HISTORY

Referred by: Neurosurgery
Previous Treatment: Previously resected

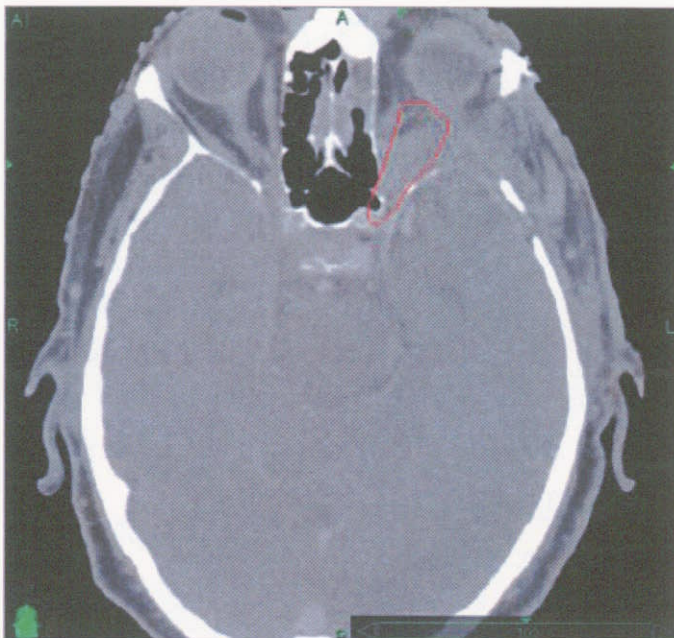
Case History

History of progressive loss of visual acuity and peripheral vision. Patient was referred for resection. Patient complained of post-surgical retrobulbar pain and discomfort.

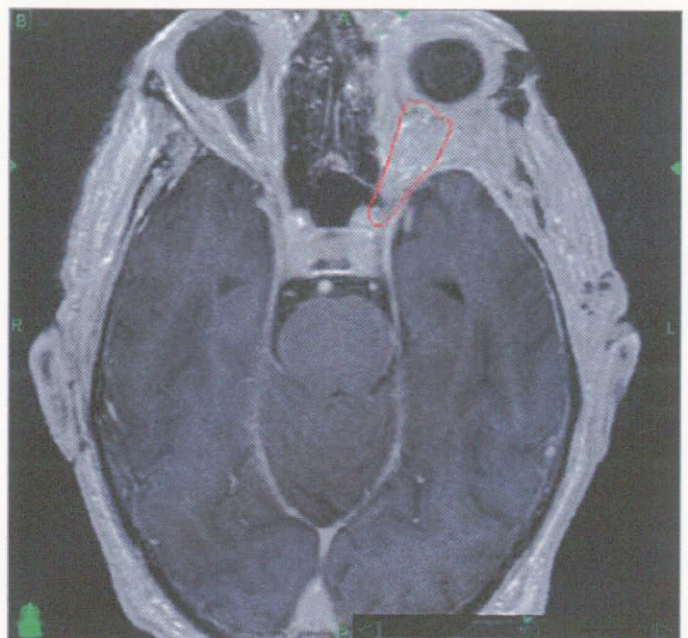
CyberKnife® Treatment Rationale

This lesion is prone to recurrence so a recommendation to perform adjunctive radiosurgery to the resection bed was made by the neurosurgeon.

Due to the risk of recurrence and intimate association of the lesion with the optic nerve, the CyberKnife® System was selected. SRS will reduce the risk of encroachment into the optic chiasm and risk to the sighted eye. Studies report hypofractionation to be safer and effective for optic nerve meningiomas.¹



Pre-treatment CT image showing target lesion.



Pre-treatment MR image showing target lesion.

LEFT OPTIC NERVE MENINGIOMA (WHO GRADE 2)

TREATMENT DETAILS

Tumor Volume: 3.1 cc
Imaging Technique(s): CT, MRI
Rx Dose & Isodose: 25 Gy to 75%
Conformality Index: 1.3
Tumor Coverage: 95.7%
Number of Beams: 170

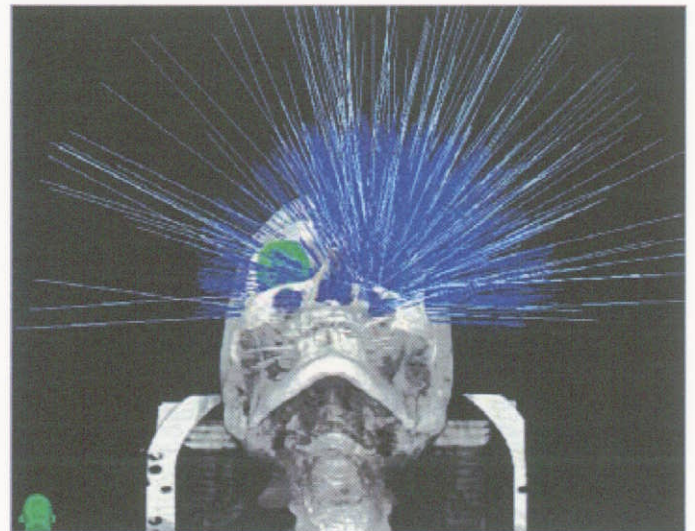
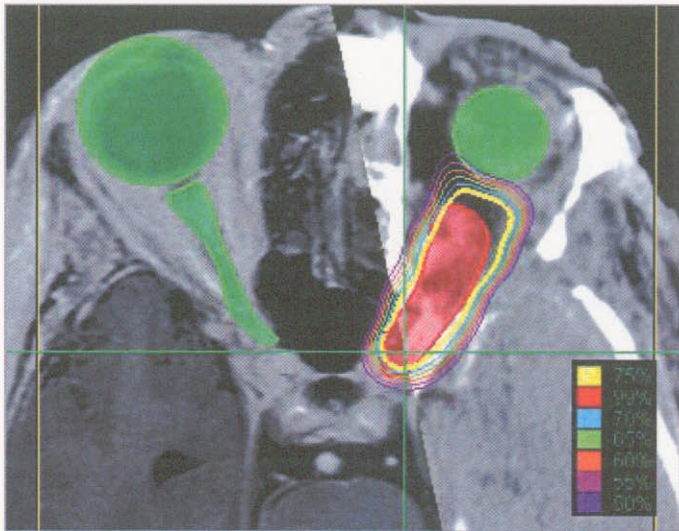
Fractions / Treatment Time: 5 / 50 minutes per fraction
Path Template: 3 path 800 mm
Tracking Method: 6D Skull Tracking
Collimator(s): 10 mm

Planning Process and Goals

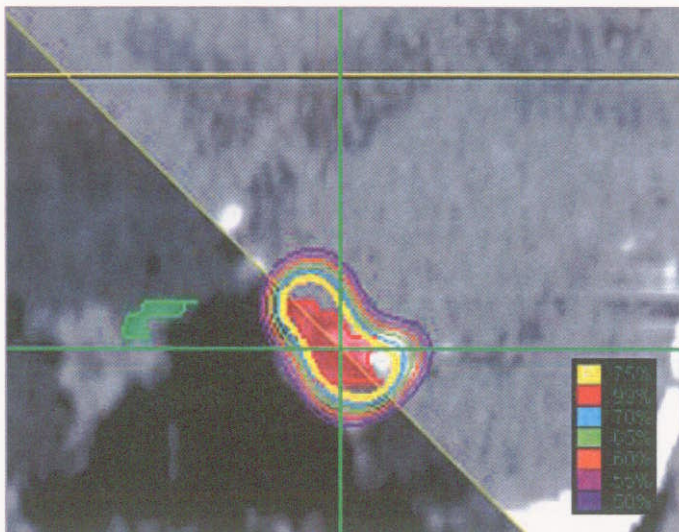
The treatment plan that was developed covered 95.7% of the tumor target volume with the 75% isodose line. The patient underwent thermoplastic immobilization and simulation, followed by CT and MR imaging localization for CyberKnife treatment planning purposes.

Treatment Delivery

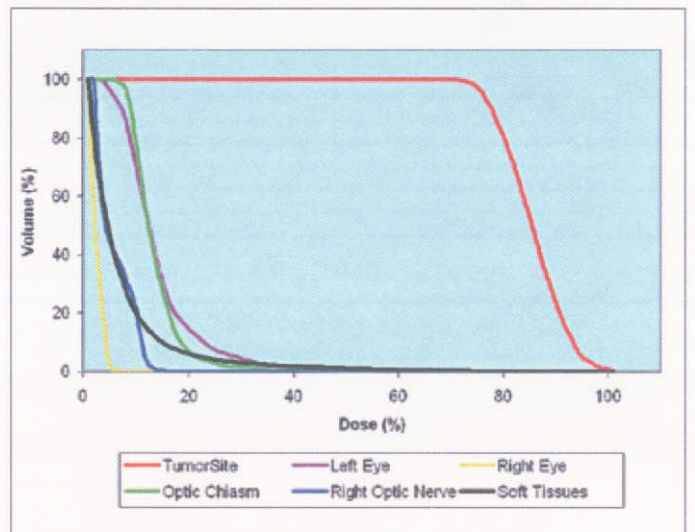
The prescription was set at 25 Gy, delivered in five fractions of 5 Gy each. The treatment was delivered without difficulty. The patient tolerated the procedure well with some vague mild complaints of left frontal sinus irritation. He specifically denied any headaches, nausea, vomiting, reduced vision in the left eye, or cranial neuropathies.



Non-isocentric beam geometry of the solution.



Fused (MR/CT) - Axial and Coronal view of target and dose distribution.



Dose Volume Histogram for target volume and critical structures.